

Clinical Observations on the New Epi-Guide® Barrier Matrix in Periodontological and Implantological Indications

Clinical procedure and scientific background of the regenerative therapy of intra-osseous defects

author_Frederic Hermann, Germany

Today's regenerative periodontal therapy covers a broad field and offers many different (micro) surgical techniques for the consolidation of intra-osseous defects. It uses a large number of different procedures and materials such as root surface pretreatment, transplantation and implantation of different bone regeneration materials, the use of enamel matrix proteins, and coverage of defects with a soft-tissue inhibiting barrier membrane (guided tissue regeneration, GTR). By contrast with conventional modes of periodontal therapy, where tissue repair is effected by long junctional epithelium, the objective of regenerative therapeutic approaches is to achieve the near-complete restoration of all architectural and functional aspects of the periodontal system (root cement, periodontal ligament, alveolar bone). However, it is impossible to differentiate clinically (ie by probing) between therapeutic success due to tissue repair and therapeutic success due to tissue regeneration. Radiological examinations may

provide a first indication (bone gain). Concrete evidence could only be provided by histological examination, which for obvious reasons is not performed. The parameter available under clinical conditions to objectify therapeutic success is attachment gain.

Previous Publications

A review of the recent literature shows that there are usually no statistically significant differences in treatment outcomes between membrane-supported GTR therapy and the use of enamel matrix proteins.¹ Depending on the baseline situation, a clinical attachment gain of between 2 and 4 mm is usually attained. This contrasts with conventional mechanical infection control with its resulting 1 to 1.5 mm of attachment gain. There are currently no predictable procedures for the therapy of lower molars with Class III furcation involvement and of maxillary furcation involvement.² It has also been shown

Fig. 1_3-D architecture of the Epi-Guide® membrane.

Fig. 2_Preoperative radiograph.

Fig. 3_Postoperative radiograph.




Fig. 1

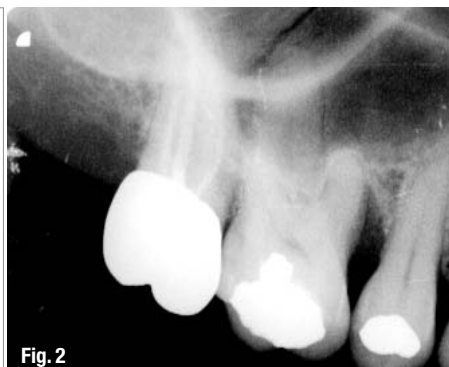


Fig. 2

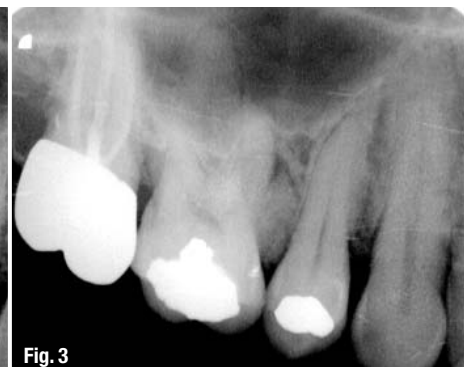

Fig. 3

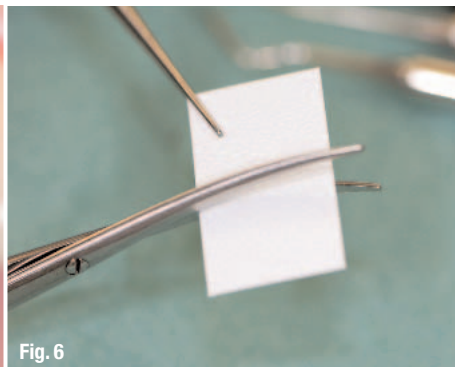
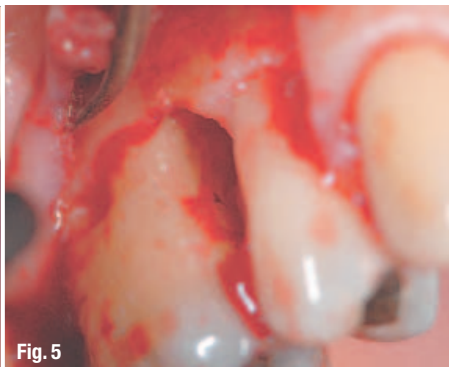
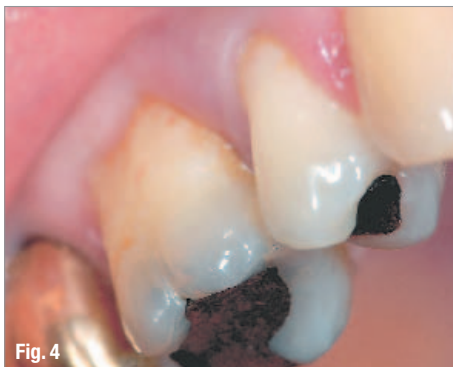Fig. 4_Preoperative buccal view.
Fig. 5_The extent of the defect.
Fig. 6_Trimming the membrane.

that root conditioning (eg, using citric acid) does not improve the clinical regeneration outcome.^{2,3,4}

The prerequisites for a predictable regenerative therapy are reflected by the following parameters:

1. Primary closed healing (submerged)
2. Immobilization of mobile teeth (stability)
3. A root surface pre-treated by curettage and by removing the smear layer (surface)
4. Maintenance of a cavity/barrier (space)

In addition to factors associated with the defect (such as width, depth, number of walls), treatment success will depend on factors related to the patient (smoking, compliance, plaque control, general health) and to the treatment (surgery, membrane exposure, antibiotic therapy).

Materials and Methods— The Epi-Guide® Membrane

Three-Layer Technology

Epi-Guide® is a uniquely structured three-dimensional bioresorbable membrane with many applications within guided tissue regeneration (GTR) and guided bone regeneration (GBR). This internal structure creates a gradient of density designed to allow fibroblasts and epithelial cells to enter the hollow spaces and to attach themselves to the walls, stabilizing these cells in the process. The innovative structure is easily recognizable in cross-section: The inner layer, featuring large and closed pores, transforms into a chamber-like structure in the intermediate layer and then into the highly porous outer layer, also featuring large

pores (Figure 1). The membrane aligns the growth of fibroblasts and epithelial cells so epithelial migration is prevented during subsequent healing stages. The structure and integrity are maintained for more than six weeks after implantation. The resorption of the barrier matrix is completed within six to twelve months.

Structure and Characteristics

The Epi-Guide® barrier matrix comes in 18x30mm (0.7 x 1.2 in.) rectangles. For easier differentiation, the surface facing the soft tissue has an embossed relief structure. Epi-Guide® is highly hydrophilic and will accommodate a large amount of blood in the intermediate chamber layer; the ingrowth of epithelial cells is prevented. In this manner, the barrier matrix serves as a placeholder for the development of bone and periodontal tissue.

Resorption Behavior

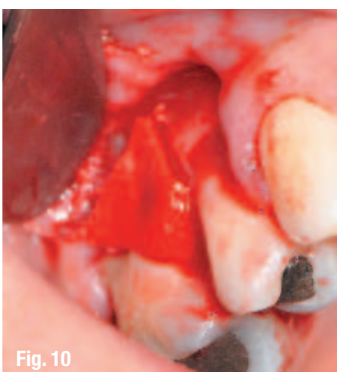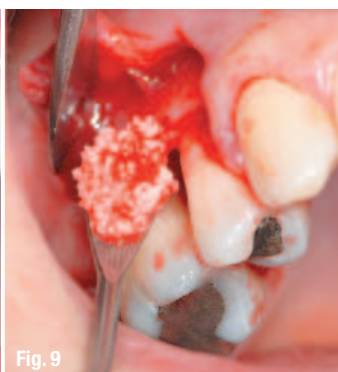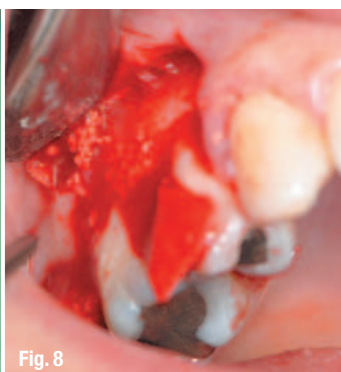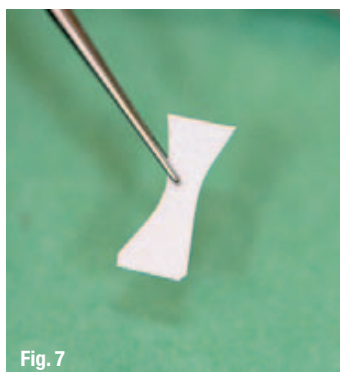
It was shown in histological examinations performed six weeks postoperatively that inflammation-free collagen fibers had formed in the barrier matrix. The architecture and the structure of the barrier had remained stable. After three weeks, as the formation of collagen fibers continues, bioresorption sets in; the matrix, however, continues to serve its function. After approximately 12 months, Epi-Guide® will have been completely resorbed. No second-stage surgery is required. The membrane surface with its open and interconnected pores counteracts suture dehiscence and gingival recession. It should be emphasized that any dehiscence or recession – should they occur after all – are very well tolerated by the membrane.

Fig. 7_ Optimally tailored to the intraosseous defect.

Fig. 8_ Membrane adaptation.

Fig. 9_ Filling the defect with activated β -TCP (Cerasorb® M/curasan AG).

Fig. 10_ Complete defect coverage with β -TCP and the Epi-Guide® barrier matrix.



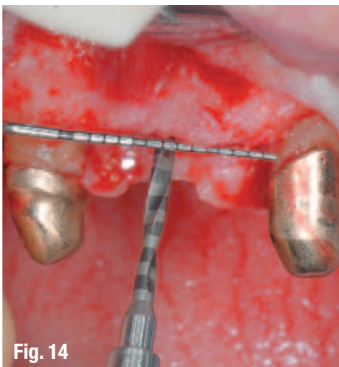
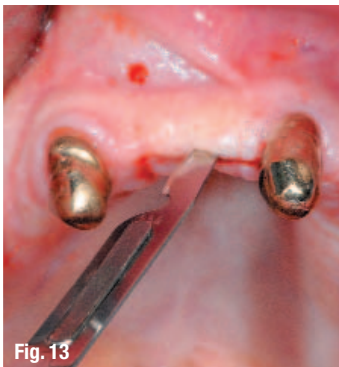
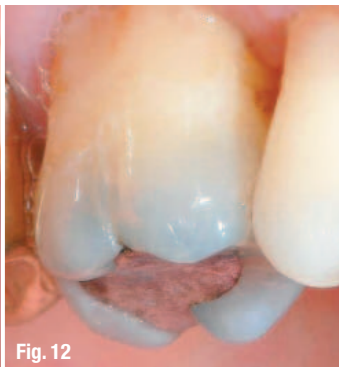
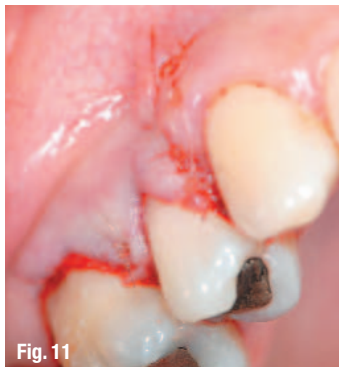
Fig. 11_The suture is impervious to saliva.

Fig. 12_Clinical intraoral situation after three months.

Fig. 13_The incision on top of the alveolar ridge.

Fig. 14_Positioning and pilot drilling.

Epi-Guide® in Clinical Studies on Humans

In a multicenter study including 40 patients with bilateral Class II furcations defects, Vernino et al.⁵ examined the influence of three-dimensional polylactide barriers (Epi-Guide® and Guidor) on the regeneration of hard tissues. The amount and quality of new bone formed was evaluated one year postoperatively by surgical reentry. The results for three centers showed significantly better results for Epi-Guide® with regard to the reduction of the vertical component. The same study also showed that exposition within the first eight weeks occurred markedly less frequently with Epi-Guide® than with the reference product.

_Case Reports

Case #1: Periodontological Indication

The patient was 39 years old at baseline. Her general health was good. Extraoral examination did not reveal any pathological findings. The intraoral situation was characterized by soft and hard supragingival concretions. All teeth exhibited positive sensitivity. The gingival margin in all quadrants exhibited only moderate localized inflammatory changes. A swollen and reddened interdental papilla was found between teeth 15 and 16. Probing depths were between 2 and 4 mm, locally reaching 8 mm at 15 and 16. No pathological tooth mobility was present.

The radiological examination showed pronounced radical bone defect reaching the apical third (Figures 2 and 3, pre- and postoperative radiographs).

The microbiological examination of the subgingival plaque demonstrated the presence of Actinobacil-

lus actinomycetemcomitans and, in connection with the clinical findings, motivated a diagnosis of localized aggressive periodontitis.

Treatment

The surgical therapy was preceded by anti-infectious therapy, consisting of closed subgingival curettage accompanied by antibiotics (amoxicillin + metronidazole; Van Winkelhoff, 1989) and 0.12% chlorhexidine digluconate rinses. When the result of the treatment was assessed 10 weeks later, probing depths of 7 mm persisted at teeth 15 and 16. Subsequent surgical therapy provided for the regeneration of the intraosseous defect using the new resorbable Epi-Guide® barrier matrix (curasan AG, Kleinostheim, Germany) for guided tissue regeneration. Based on the morphology of the defect as uncovered intraoperatively (two-walled defect), additional support was consciously provided by applying a bone regeneration material (β -TCP/Cerasorb® M, 500–1,000 μ m, curasan AG) to preserve the cavity. The surgical procedure is illustrated in Figures 4 to 11. The membrane and flap were additionally stabilized by an offset suture with resorbable suture material above the defect area. Vertical interrupted sutures were used to reposition the papilla.

Outcome

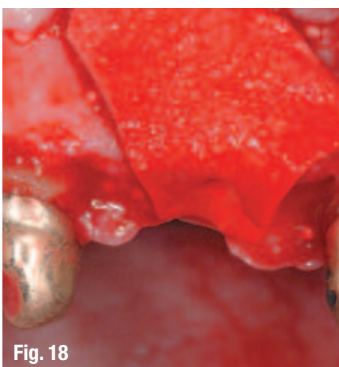
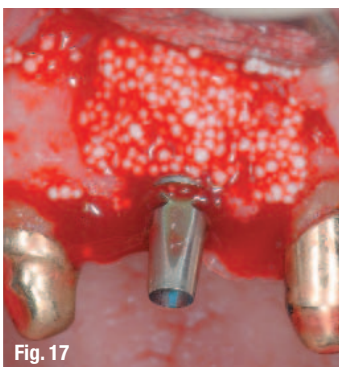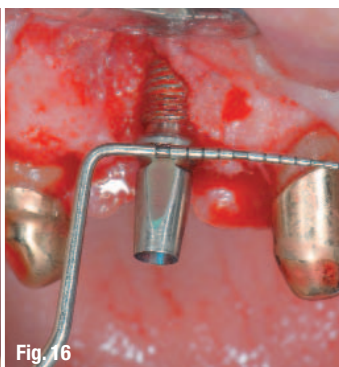
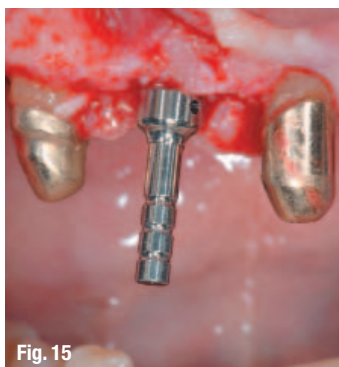The wound healing process was free of complications. An attachment gain of 2.5 mm was subsequently measured. A slight papillary recession of 1 to 3 mm in the regeneration area is frequently seen and could not be predictably avoided even in this

Fig. 15_Parallelization check.

Fig. 16_Inserted REVOIS® implant (curasan AG) with vestibular bony dehiscence.

Fig. 17_Lateral augmentation with β -TCP (Cerasorb® M/curasan AG).

Fig. 18_Fully adapted membrane above the defect.



case despite the use of microsurgical methods and papilla preservation techniques. The patient should always be fully informed of this risk ahead of the operation, especially in the case of procedures in the esthetic zone.

Probing depth decreased to 3 mm, which is a level that the patient can easily maintain, yielding a favorable long-term prognosis of freedom from inflammation if regular recalls are made.

Case #2: Implantological Indication

The patient was 67 years old at baseline. His general health was good. Extraoral examination did not reveal any pathological findings. The alveolar range between teeth 13 and 23 showed moderate vertical and pronounced horizontal atrophy. Following periodontological pretreatment, the existing maxillary telescopic restoration increasingly lost its retention, and it was decided to add abutments by implantological means. In addition, the patient requested a fixed restoration without a palatal bar.

Treatment

Following a minimally invasive incision along the top of the alveolar ridge (13–21) and mobilization of a mucoperiosteal flap, placement of a Revois® implant was accompanied by concurrent widening of the alveolar ridge using the bone-splitting technique. Following placement of the implant, the crestal aspect of the vestibular bony lamella fractured and developed a dehiscence, which was augmented with β -TCP (Cerasorb® M, 500–1,000 μ m, curasan AG) and covered with a resorbable membrane (Epi-Guide®, curasan AG; see Figures 12 to 18).

Outcome

After tension-free primary wound closure, wound healing proceeded without complications, with no membrane exposure or inflammatory reactions. The vestibular contours of the alveolar ridge could be restored in their entirety.

_Discussion

The two cases from regenerative periodontology and augmentative implantology exemplify the advantages of the fully synthetic Epi-Guide® resorbable polylactide membrane (curasan AG). The clinical photographs demonstrate ease of handling, ease of contouring and rapid absorbency of blood from the defect region, important prerequisites for rapid and safe intraoperative membrane placement. Other favorable aspects are close tissue adaptation and good tissue integration, along with the barrier function of the material, substantially reducing the risk of membrane exposure. No postoperative complications have occurred in connection with this membrane in any of the cases treated so far.

Generally speaking, the use of resorbable membranes makes an additional surgical intervention unnecessary, which is well in line with the concept of minimally invasive dental care. An advantage is the fully synthetic nature of the membrane, which makes forensic aspects figure less prominently and reduces the time needed for patient education. Advantages in clinical procedures are particularly evident in combination with a synthetic resorbable bone regeneration material such as β -TCP (Cerasorb® M, curasan AG).⁶

On the other hand, care must be taken to ensure primary wound closure when working with resorbable membranes in order to prevent postoperative infection of the regenerative area. Since tension-free wound closure cannot be guaranteed and membrane exposure cannot be predictably excluded in every case, the exclusive use of resorbable membranes for every conceivable situation cannot be recommended. It is also necessary to pay attention to the additional stress on the tissues caused by the process of membrane resorption. When regenerative techniques are used in the esthetic zone, the patient must be informed about the possibility of gingival recession ahead of time.

_Conclusion

We can conclude that the improvements that were made to the proven Epi-Guide® resorbable barrier matrix have considerable clinical advantages. Compared to the predecessor material, the matrix is easier to handle intraoperatively, while at the same time exhibiting improved resorption and adaptation characteristics, ensuring safe placement above the bone regeneration area. Postoperative wound healing was free of complications in all cases. Both the bone regeneration material used and the membrane proved to be very well tolerated clinically. This article presents exemplary anecdotal case reports. Results from controlled clinical studies including histological evaluations would be desirable in order to document the current good results in a more stringently formalized manner based on a greater number of patients.

The literature list can be requested from the author.

_author	implants
Dr Frederic Hermann	
AZZ Ambulantes Zahnmedizinisches Zentrum Poststr. 15 6300 Zug Switzerland Phone: +41-41/710 91 70 E-mail: frederic.hermann@gmx.de	